

Lateral femoral notch depth is not associated with increased rotatory instability in ACL-injured knees: a quantitative pivot shift analysis

Ajay C. Kanakamedala¹ · Jeremy M. Burnham¹ · Thomas R. Pfeiffer² · Elmar Herbst³ · Marcin Kowalczyk¹ · Adam Popchak¹ · James Irrgang¹ · Freddie H. Fu¹ · Volker Musahl¹

Received: 13 September 2017 / Accepted: 30 October 2017 / Published online: 8 November 2017
© European Society of Sports Traumatology, Knee Surgery, Arthroscopy (ESSKA) 2017

Abstract

Purpose A deep lateral femoral notch (LFN) on lateral radiographs is indicative of ACL injury. Prior studies have suggested that a deep LFN may also be a sign of persistent rotatory instability and a concomitant lateral meniscus tear. Therefore, the purpose of this study was to evaluate the relationship between LFN depth and both quantitative measures of rotatory knee instability and the incidence of lateral meniscus tears. It was hypothesized that greater LFN depth would be correlated with increased rotatory instability, quantified by lateral compartment translation and tibial acceleration during a quantitative pivot shift test, and incidence of lateral meniscus tears.

Methods ACL-injured patients enrolled in a prospective ACL registry from 2014 to 2016 were analyzed. To limit confounders, patients were only included if they had primary ACL tears, no concurrent ligamentous or bony injuries requiring operative treatment, and no previous knee injuries or surgeries to either knee. Eighty-four patients were included in the final analysis. A standardized quantitative

pivot shift test was performed pre-operatively under anesthesia in both knees, and rotatory instability, specifically lateral compartment translation and tibial acceleration, was quantified using tablet image analysis software and accelerometer sensors. Standard lateral radiographs and sagittal magnetic resonance images (MRI) of the injured knee were evaluated for LFN depth.

Results There were no significant correlations between LFN depth on either imaging modality and ipsilateral lateral compartment translation or tibial acceleration during a quantitative pivot shift test or side-to-side differences in these measurements. Patients with lateral meniscus tears were found to have significantly greater LFN depths than those without on conventional radiograph and MRI (1.0 vs. 0.6 mm, $p < 0.05$; 1.2 vs. 0.8 mm, $p < 0.05$, respectively).

Conclusion There was no correlation between lateral femoral notch depth on conventional radiographs or MRI and quantitative measures of rotatory instability. Concomitant lateral meniscus injury was associated with significantly greater LFN depth. Based on these findings, LFN depth

✉ Volker Musahl
musahlv@upmc.edu

Ajay C. Kanakamedala
ack55@pitt.edu

Jeremy M. Burnham
jburnh@gmail.com

Thomas R. Pfeiffer
t.pfeiffer@email.de

Elmar Herbst
elmar.herbst@gmail.com

Marcin Kowalczyk
kowalczykm@upmc.edu

Adam Popchak
ajp64@pitt.edu

James Irrgang
jirrgang@pitt.edu

Freddie H. Fu
ffu@upmc.edu

¹ Department of Orthopaedic Surgery, Center for Sports Medicine, UPMC Rooney Sports Complex, University of Pittsburgh Medical Center, 3200 S Water Street, Pittsburgh, PA 15203, USA

² Department of Orthopaedic Surgery, Trauma Surgery and Sports Medicine, Cologne Merheim Medical Center, Witten/Herdecke University, 51109 Cologne, Germany

³ Department of Orthopaedic Sports Medicine, Technical University Munich, 81675 Munich, Germany

should not be used as an indicator of excessive rotatory instability, but may be an indicator of lateral meniscus injury in ACL-injured patients.

Level of evidence Prognostic level IV.

Keywords Anterior cruciate ligament · Lateral femoral notch · Lateral notch · Rotatory laxity · Knee · Pivot shift · ACL · Quantitative pivot shift · Rotatory instability

Introduction

The “lateral notch sign”, or the presence of a deep lateral femoral notch (LFN), is a radiographic sign that has been observed in chronically anterior cruciate ligament (ACL)-injured patients with persistent rotatory instability [17, 26]. In the initial description of this sign, it was observed that the lateral femoral notch would progressively deepen in patients who were experiencing subjective instability, i.e., repeated episodes of “giving way” [26]. Some studies have postulated that a deep lateral notch is the result of chronic rotatory instability, more specifically anterior subluxation of the lateral tibial plateau making recurrent contact with the lateral femoral condyle [5, 17, 24, 26]. Other studies suggest that it may be the result of the progression of occult bone lesions occurring secondary to traumatic injury and valgus force at the moment of ACL tear, partly analogous to the Hill–Sachs lesion during shoulder dislocations [5, 17, 24, 26]. The lateral notch sign has also been shown to correlate with the incidence of lateral meniscus tears [6], which may be due to the proximity of the lateral meniscus to the lateral condylopatellar sulcus, the anatomic correlate to the radiographic LFN. It is possible that the same traumatic forces that lead to a deepened LFN also lead to lateral meniscus tears [5, 6].

Given that bony morphology plays a significant role in knee kinematics and rotatory instability [10, 18, 22], further understanding of the relationship between a specific aspect of bony morphology, specifically the lateral femoral notch, and rotatory instability could assist in understanding and addressing the underlying causes for persistent rotatory instability after ACL reconstruction. Increased rotatory instability after ACL reconstruction, assessed by methods such as the pivot shift test, has been shown to correlate with worse patient-reported outcomes as well as increased risk of osteoarthritis [2, 11, 13]. A rigorous analysis and quantification of the relationship between LFN depth and rotatory instability could provide clinicians with a new tool for detecting patients at risk for excessive rotatory stability and worsened post-operative outcomes after ACL reconstruction. Moreover, while one prior study did find a deepened LFN to be in association with recurrent anterior translation of the tibial plateau, it did not specifically quantify the degree of

rotatory instability or how LFN depth might influence rotatory instability [17].

The purpose of this study was to evaluate the relationship between lateral femoral notch (LFN) depth and quantitative measures of rotatory knee stability, specifically lateral compartment translation and tibial acceleration during a quantitative pivot shift test. It was hypothesized that greater LFN depth would be correlated with an increase in rotatory instability, quantified by lateral compartment translation and tibial acceleration during a quantitative pivot shift test. It was also hypothesized that greater LFN depth would be correlated with the presence of a lateral meniscus tear. Other factors, including age, gender, and BMI, were also examined for an association with LFN depth.

Materials and methods

ACL-injured patients enrolled in a prospective ACL registry and undergoing primary ACL reconstruction by a single orthopaedic surgeon at the reporting institution from June 2014 to April 2016 were analyzed in this study. Patients were included if they had a primary ACL tear, no concurrent ligamentous or bony injury requiring operative treatment, and no history of the previous knee injuries or surgery to the ACL-injured or contralateral extremities. The presence of concomitant ligamentous or bony injuries was designated as exclusion criteria to minimize any factors that might confound the relationship between notch depth and rotatory instability in ACL-injured knees. Patients' charts were reviewed for data regarding baseline characteristics including age and BMI. Intra-operative reports were reviewed to collect data regarding the presence of concomitant injuries including ligamentous or bony injuries. Information regarding meniscus tears including the tear pattern was also collected.

Standard lateral radiographs and sagittal magnetic resonance images (MRI) of the ACL-injured knee were evaluated by a single-blinded observer for depth of the LFN as previously described (Fig. 1) [26]. In brief, a line tangent to the lateral femoral condyle articular surface was drawn across the notch. Notch depth was measured perpendicular from this line to the deepest point of the lateral femoral notch. The number of patients with a positive lateral notch sign defined based on prior literature as an LFN depth of 2 mm [6, 26], was tabulated.

To determine inter-observer reliability, 34 radiographs and 28 MR images from the cohort were randomly chosen, and the same measurements were performed by a second blinded and independent observer. An intra-class correlation coefficient (ICC) was calculated for the measurements of the two observers. To qualify the ICC, the following commonly used guidelines were

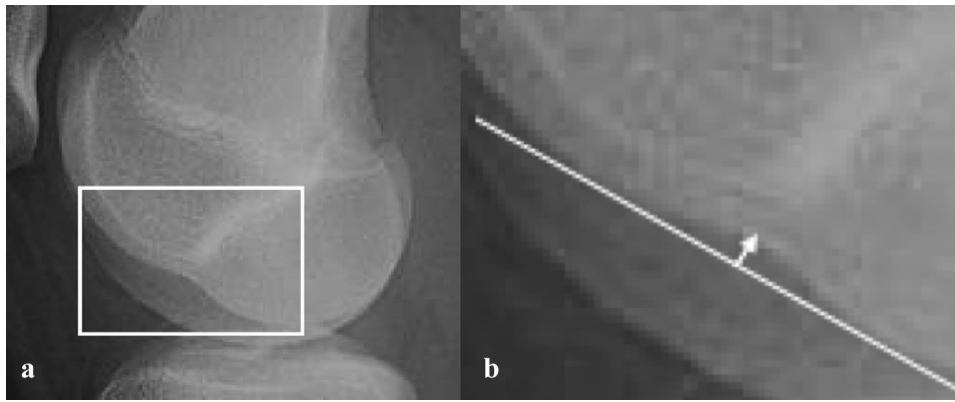


Fig. 1 Method of measuring the lateral femoral notch (LFN) on plain radiographs. **a** A high quality lateral radiograph without malrotation must be obtained. Example shown here. **b** Magnification of area outlined in **(a)**. A line is then drawn tangential to the articular surface of the lateral femoral condyle, across the lateral femoral notch (or

condylopatellar sulcus). After this line (white line) is drawn, a second line (white arrow) is drawn perpendicular to measure the deepest portion of the LFN. The distance of this line is the LFN depth. The same method can be performed on MRI. When using MRI, the sagittal slice with the deepest LFN is chosen

set: ($ICC \leq 0.2$) slight agreement; ($0.21 \leq ICC \leq 0.40$) fair agreement; ($0.41 \leq ICC \leq 0.60$) moderate agreement; ($0.61 \leq ICC \leq 0.80$; $0.81 \leq ICC \leq 1$) almost perfect agreement [14].

The use of tablet-based image analysis software and accelerometer sensors for quantifying rotatory instability has been previously described and validated [9, 15, 16, 20]. Briefly, three circular yellow markers, $\frac{3}{4}$ inch in diameter (Color Coding Labels, Avery Dennison Corporation, Pasadena, CA, USA), were applied to the skin over the fibular head, lateral epicondyle, and Gerdy's tubercle. A commercial triaxial accelerometer (Kira, Orthokey LLC, DE, USA) was fixed to the skin between Gerdy's tubercle and the lateral aspect of the anterior tuberosity. A standardized pivot shift test was performed by the senior surgeon in both knees [8, 21]. Using specially designed computer tablet software, lateral compartment translation of the knee and tibial acceleration during the pivot shift test were calculated. Both the image analysis and accelerometer-based methods of measuring rotatory instability have been previously validated and shown to have acceptable reliability [1, 3, 9, 15, 19, 20]. The reported intra-class correlation coefficients (ICC) for the intra- and inter-tester reliabilities for the tablet-based method are 0.75 and 0.73. The reported ICC for the intra-tester reliability of the accelerometer-based method is 0.9. The image analysis and accelerometer-based methods have accuracies of <0.1 mm and 0.03 m/s², respectively. Side-to-side differences were calculated by subtracting the measurement of the contralateral knee from that of the ACL-injured knee. Prior to commencing the study, approval was obtained from the University of Pittsburgh Institutional Review Board (PRO09030172).

Statistical analysis

Descriptive statistics, including means and standard deviations (SD), were calculated for all continuous variables including age, BMI, and LFN depth. Frequency counts and percentages were determined for categorical variables including gender, presence of medial or lateral meniscus tears, and prevalence of LFN sign. Data for continuous variables were tested for normality using the Shapiro–Wilk test. After data collection was complete, it was found that distributions for all continuous variables were non-parametric, and therefore, Spearman's correlation coefficient was used to analyze correlations between continuous variables, including quantitative measures of rotatory instability. To qualify the strength of each correlation, the following scale was used for the absolute value of the correlation coefficient (r): weak ($r < 0.3$); moderate ($0.3 \leq r < 0.5$); and strong ($0.50 \leq r \leq 1.0$). An independent t test was used to analyze for differences in LFN depth based on the presence of a medial or lateral meniscus tear and gender. Analyses were performed with SPSS (v22; IBM Corp). Significance was set at $p < 0.05$. A post hoc power analysis was performed using G*Power 3.1.9.2 (Franz Paul, Kiel, Germany) to calculate the power and assess the sample size of the present study. Based on the results of the Spearman's rank correlation coefficient regarding the correlation between anterior translation of the lateral compartment of the knee during a pivot shift test and LFN depth on radiograph, a power of 0.67 was calculated.

Results

Eighty-four patients met inclusion criteria and were included in this study. The cohort included 36 females and 48 male subjects with a median age of 22.0 years (range 12–51). The median BMI was 25.0 (range 18.7–43.9). Conventional standard lateral radiographs and MR images were available for 66 and 64 patients, respectively. Complete data sets were otherwise available for all patients. The mean LFN depths on radiograph and MRI were 0.8 mm (SD=0.7 mm) and 1.0 mm (SD=0.7 mm), respectively. The ICC for inter-observer reliability was 0.87 for radiographs and 0.92 for sagittal MR images, thus indicating almost perfect agreement according to the initially defined guidelines. There was a strong correlation between LFN depths as measured on radiograph and MRI ($\rho=0.83$, $p<0.05$). Positive LFN signs (LFN depth >2 mm) were observed in three patients on radiograph (4.7%) and six patients on MRI (9.1%). An intra-operative photo of an enlarged lateral femoral notch and the corresponding MRI are shown in Fig. 2.

Results of quantitative pivot shift testing for the entire cohort are shown in Table 1. Data regarding the relationship between LFN depth on radiograph and MRI and quantitative

measures of rotatory instability are shown in Table 2. There were no significant correlations between LFN depth on either imaging modality and ipsilateral lateral compartment translation or acceleration during a pivot shift test, anterior tibial translation during the Lachman test or side-to-side differences in these measurements.

Data regarding the incidence of meniscus tears and individual tear patterns are shown in Table 3. The mean LFN depth was significantly greater in patients with a lateral meniscus tear ($n=43$) than those without ($n=31$) on both radiograph and MRI (0.6 vs. 1.0 mm, $p<0.05$; 0.8 vs. 1.2 mm, $p<0.05$, respectively). There was no significant difference in LFN depth between patients with ($n=35$) and without ($n=49$) a medial meniscus tear. Neither the presence of a medial or lateral meniscus tear was independently associated with ipsilateral lateral compartment translation or acceleration during a pivot shift test, anterior tibial translation during the Lachman test, or side-to-side differences in these measurements.

There was a significant weak negative correlation between greater age and increased LFN depth on radiograph and MRI ($\rho = -0.281$, $p<0.05$; $\rho = -0.294$, $p<0.05$, respectively). There were no significant differences in LFN

Fig. 2 Example of Radiographic and Intra-Operative Lateral Femoral Notch (LFN). **a** MRI depicting lateral notch sign (white box). **b** Intra-operative confirmation of deepened LFN (black arrow) at the lateral condylopatellar sulcus. Both of these images were obtained from the same individual

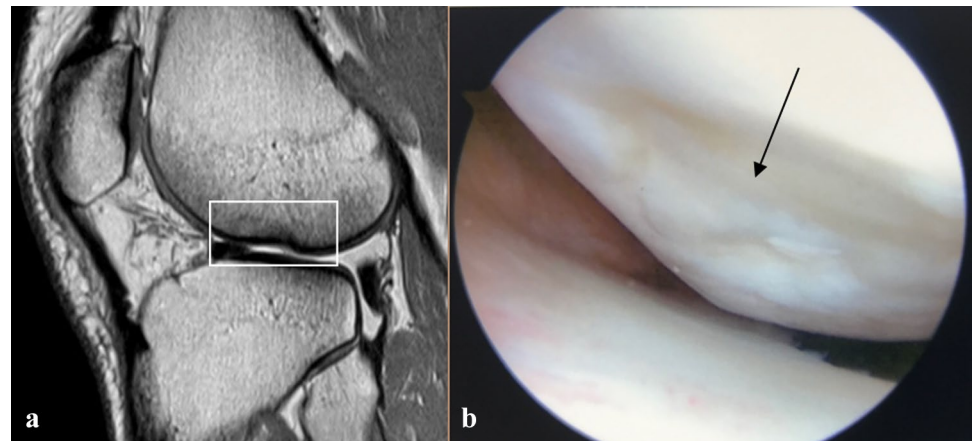


Table 1 Quantitative pivot shift values ($n=84$)

	Total ($n=84$)	MRI ($n=64$)	Radiograph ($n=66$)
Translation (mm)			
Absolute value	3.5 ± 2.0	3.6 ± 2.1	3.6 ± 2.1
Side-to-side difference	2.6 ± 1.9	2.7 ± 1.9	2.6 ± 1.9
Tibial acceleration (m/s^2)			
Absolute value	5.29 ± 2.64	5.25 ± 2.78	5.26 ± 2.75
Side-to-side difference	1.76 ± 2.43	1.87 ± 2.63	1.63 ± 2.55

Descriptive statistics, including means and standard deviations, were calculated for the results of quantitative pivot shift testing. All values reported as mean \pm standard deviation

Translation lateral compartment translation of the knee during a quantitative pivot shift test measured by PIVOT technology. *Tibial acceleration* acceleration of tibia during a quantitative pivot shift test measured by an accelerometer attached to the proximal tibia (KiRA; Orthokey Italia Srl). *MRI* sagittal view of magnetic resonance image. *Radiograph* standard lateral radiograph

Table 2 Correlations between LFN depth and quantitative pivot shift (Spearman's rho)

	LFN depth (radiograph) (n = 66)	p value	LFN Depth (MRI) (n = 64)	p value
Translation				
Absolute value	0.3	(ns)	0.0	(ns)
Side-to-side difference	- 0.1	(ns)	- 0.1	(ns)
Tibial acceleration				
Absolute value	0.0	(ns)	0.0	(ns)
Side-to-side difference	0.0	(ns)	0.1	(ns)

Spearman's rho coefficient was used to test for correlations between quantitative measures of rotatory instability and lateral femoral notch (LFN) depth on both standard lateral radiographs and sagittal views of magnetic resonance imaging (MRI). Significance was set at $p < 0.05$. There were no significant correlations between quantitative measures of rotatory instability and LFN depth. All values, except for p values, given as Spearman's rho coefficient

Translation anterior translation of the lateral compartment of the knee during a quantitative pivot shift test measured by PIVOT technology. *Tibial acceleration* acceleration of tibia during a quantitative pivot shift test measured by an accelerometer attached to the proximal tibia (KiRA; Orthokey Italia Srl). *LFN* lateral femoral notch. *Radiograph* standard lateral radiograph of the knee. *MRI* sagittal view of magnetic resonance image. *ns* not significant

Table 3 Incidence of meniscus injuries (n = 84)

	n (%)
Lateral meniscus injury	25 (29.8%)
Medial meniscus injury	17 (20.2%)
Combined lateral and medial meniscus injuries	18 (21.4%)
No meniscus injury	24 (28.6%)

Data regarding the incidence of meniscus tears, including both counts and percentages, are shown. All values reported as n (% of total cohort)

depth between males and females. There was no significant correlation between BMI and LFN depth on either imaging modality.

Discussion

The primary finding of this study is that a deep lateral femoral notch is not significantly associated with increased rotatory knee instability, disproving the hypothesis under study. This suggests that the presence of a deep lateral femoral notch should not be used as a sign of increased rotatory instability. These data are in contrast to the initial description of the lateral notch sign in which it was observed that

ACL-injured patients with chronic anterior subluxation of the lateral tibial plateau were found to have progressively deepening lateral femoral notches [17].

While patients with concomitant ligamentous injuries or intra-articular fractures were excluded to limit potential confounders, it is possible that there, nonetheless, were other factors that obscured the relationship between LFN depth and rotatory knee instability. It is conceivable that lateral notch may lead to altered knee kinematics and subjective instability in ways that are not captured by the measurements utilized in the present study. For example, increased LFN depth could possibly lead to reduced surface contact area between the distal femur and proximal tibia and predispose patients to instability, particularly during flexion. While there are multiple case reports of arthroscopic and open reductions being performed to reduce impacted fractures at the site of the deepened LFN and restore joint surface congruity [7, 23, 25], it is unclear how an enlarged LFN affects kinematics at the knee. Future biomechanical studies will be helpful in investigating how the enlarged lateral femoral notch might engage with the tibia, particularly when valgus stresses are applied along with external tibial rotation.

This finding is important given the increasing evidence that there are abnormal kinematics in the knee after ACL reconstruction, including excessive rotatory instability [4, 12, 27] and that there is an association between excessive rotatory instability and significantly worsened post-operative outcomes [2, 11, 13]. There is increasing interest in developing techniques to identify patients at risk for post-operative rotatory instability who may benefit from additional procedures such as extra-articular tenodesis. Given the potential risks of such procedures, it thus is important to recognize that, based on the data presented here which diverge from prior studies, the lateral notch sign should not be used as a sign of chronic rotatory instability.

Prior studies have found that the lateral notch sign is also significantly associated with the presence of an ACL injury and have identified cut-off values of 1.5 and 2 mm [5, 26]. The present study did not specifically evaluate this, but based on the previously reported on cut-off LFN depth of 2 mm for identifying ACL-injured patients, 4.7% and 9.1% of patients in the present study had positive lateral notch signs on radiographs and MR images, respectively. These data align well with a previous study of 164 patients in which 4.5% of patients with chronic ACL deficiency and rotatory knee instability and 7.5% of patients with acute ACL tears were found to have LFN depths of at least 2 mm on radiographs [6].

While it has been arthroscopically confirmed that ACL-injured patients with a radiographic lateral notch sign typically have damage to the articular cartilage to the lateral femoral condyle [6], the precise etiology remains unclear. Some authors have suggested that the deep lateral notch is

the result of recurrent subluxation of the lateral tibial plateau making repeated contact with the lateral femoral condyle [17]. Others hypothesize that the lateral notch may develop from occult bone lesions occurring from valgus stress during the initial ACL injury [5, 17, 24, 26].

Given that the measurements in the present study were performed on patients pre-operatively, it is possible that if a deepened LFN is the result of recurrent subluxation of the lateral tibial plateau, then the LFN depth did not correlate with acute rotatory instability in the ACL-injured knee. In other words, mechanisms of excessive rotatory instability in the chronic ACL-injured knee may differ from those of the acutely ACL-injured knee.

Younger age was found to have a weak positive correlation with increased LFN depth, which has also been shown in a previous study [6]. The lateral notch sign was also demonstrated to significantly correlate with the presence of lateral meniscus tears, which is also in agreement with the previous studies [6]. If the lateral notch sign does indeed represent an occult bone lesion on the lateral femoral condyle, the correlation between a deep LFN and lateral meniscus injury may be secondary to the proximity of the anterior horn of the lateral meniscus with the lateral condylopatellar sulcus, the anatomic correlate to the radiographic LFN [5, 6]. Future prospective studies will be valuable in determining whether outcomes after lateral meniscus tears are affected at all by the presence of the lateral notch sign.

This study was limited by a small sample size ($n=66$ patients with radiographs, 64 with MR images), and the power of the present study to detect a significant correlation between LFN depth on radiograph and lateral compartment translation during a pivot shift test was calculated to be 0.67. Future prospective studies will be helpful in determining whether the deepened LFN exists prior to and is a risk factor for ACL injuries.

Conclusion

There was no statistically significant correlation between lateral femoral notch (LFN) depth on radiographs or MRI with preoperative lateral compartment translation or tibial acceleration during quantitative pivot shift analysis. Based on these findings, LFN depth should not be used as an indicator of high-grade rotatory knee instability. A deepened LFN, either on imaging or on intra-operatively, may, however, be used as an indicator that the patient is more likely to have a lateral meniscus tear. This is analogous to how bone bruise patterns on MRI are used to evaluate for various ligamentous injuries. In the clinical setting, surgeons should take these data into consideration when considering additional stabilizing procedures during ACL reconstruction or arthroscopically evaluating for injuries in patients.

Compliance with ethical standards

Conflict of interest All authors declare that they have no conflict of interest.

Funding There was no external source of funding for this study.

Ethical approval Approval was obtained from the University of Pittsburgh Institutional Review Board (PRO09030172).

Informed consent Informed consent was obtained from all participants included in the study.

References

1. Arilla FV, Rahnamai-Azar AA, Yacuzzi C, Guenther D, Engel BS, Fu FH, Musahl V, Debski RE (2016) Correlation between a 2D simple image analysis method and 3D bony motion during the pivot shift test. *Knee* 23:1059–1063
2. Ayeni OR, Chahal M, Tran MN, Sprague S (2012) Pivot shift as an outcome measure for ACL reconstruction: a systematic review. *Knee Surg Sports Traumatol Arthrosc* 20:767–777
3. Berruto M, Uboldi F, Gala L, Marelli B, Albinetti W (2013) Is tri-axial accelerometer reliable in the evaluation and grading of knee pivot-shift phenomenon? *Knee Surg Sports Traumatol Arthrosc* 21:981–985
4. Bull AM, Amis AA (1998) The pivot-shift phenomenon: a clinical and biomechanical perspective. *Knee* 5:141–158
5. Cobby M, Schweitzer M, Resnick D (1992) The deep lateral femoral notch: an indirect sign of a torn anterior cruciate ligament. *Radiology* 184:855–858
6. Garth WP, Greco J, House MA (2000) The lateral notch sign associated with acute anterior cruciate ligament disruption. *Am J Sports Med* 28:68–73
7. Garth WP Jr, Wilson T (2001) Open reduction of a lateral femoral notch associated with an acute anterior cruciate ligament tear. *Arthroscopy* 17:874–877
8. Hoshino Y, Araujo P, Ahlden M, Moore CG, Kuroda R, Zaffagnini S, Karlsson J, Fu FH, Musahl V (2012) Standardized pivot shift test improves measurement accuracy. *Knee Surg Sports Traumatol Arthrosc* 20:732–736
9. Hoshino Y, Araujo P, Ahlden M, Samuelsson K, Muller B, Hofbauer M, Wolf MR, Irrgang JJ, Fu FH, Musahl V (2013) Quantitative evaluation of the pivot shift by image analysis using the iPad. *Knee Surg Sports Traumatol Arthrosc* 21:975–980
10. Hoshino Y, Wang JH, Lorenz S, Fu FH, Tashman S (2012) The effect of distal femur bony morphology on in vivo knee translational and rotational kinematics. *Knee Surg Sports Traumatol Arthrosc* 20:1331–1338
11. Jonsson H, Riklund-Ahlstrom K, Lind J (2004) Positive pivot shift after ACL reconstruction predicts later osteoarthritis: 63 patients followed 5–9 years after surgery. *Acta Orthop Scand* 75:594–599
12. Kanamori A, Zeminski J, Rudy TW, Li G, Fu FH, Woo SL-Y (2002) The effect of axial tibial torque on the function of the anterior cruciate ligament: a biomechanical study of a simulated pivot shift test. *Arthroscopy* 18:394–398
13. Kocher MS, Steadman JR, Briggs KK, Sterett WI, Hawkins RJ (2004) Relationships between objective assessment of ligament stability and subjective assessment of symptoms and function after anterior cruciate ligament reconstruction. *Am J Sports Med* 32:629–634

14. Landis JR, Koch GG (1977) The measurement of observer agreement for categorical data. *Biometrics* 33:159–174
15. Lopomo N, Signorelli C, Bonanzinga T, Muccioli GMM, Visani A, Zaffagnini S (2012) Quantitative assessment of pivot-shift using inertial sensors. *Knee Surg Sports Traumatol Arthrosc* 20:713–717
16. Lopomo N, Zaffagnini S, Signorelli C, Bigozzi S, Giordano G, Marcheggiani Muccioli GM, Visani A (2012) An original clinical methodology for non-invasive assessment of pivot-shift test. *Comput Methods Biomech Biomed Engin* 15:1323–1328
17. Losee RE, Johnson TR, Southwick W (1978) Anterior subluxation of the lateral tibial plateau. A diagnostic test and operative repair. *J Bone Joint Surg Am* 60:1015–1030
18. Malviya A, Lingard E, Weir D, Deehan D (2009) Predicting range of movement after knee replacement: the importance of posterior condylar offset and tibial slope. *Knee Surg Sports Traumatol Arthrosc* 17:491–498
19. Muller B, Hofbauer M, Rahnama-Azar AA, Wolf M, Araki D, Hoshino Y, Araujo P, Debski RE, Irrgang JJ, Fu FH (2016) Development of computer tablet software for clinical quantification of lateral knee compartment translation during the pivot shift test. *Comput Methods Biomech Biomed Engin* 19:217–228
20. Musahl V, Griffith C, Irrgang JJ, Hoshino Y, Kuroda R, Lopomo N, Zaffagnini S, Samuelsson K, Karlsson J, Oostdyk A, Rahnama-Azar AA, Arilla FV, Guenther D, Zlotnicki J, Ohashi B, Araujo P, Kurosaka M, Nagamune K, Marcheggiani Muccioli GM, Signorelli C, Bjoernsson H, Ahlden M, Desai N, Fu FH (2016) Validation of Quantitative Measures of Rotatory Knee Laxity. *Am J Sports Med* 44:2393–2398
21. Musahl V, Hoshino Y, Ahlden M, Araujo P, Irrgang JJ, Zaffagnini S, Karlsson J, Fu FH (2012) The pivot shift: a global user guide. *Knee Surg Sports Traumatol Arthrosc* 20:724–731
22. Rahnama-Azar AA, Abebe ES, Johnson P, Labrum J, Fu FH, Irrgang JJ, Samuelsson K, Musahl V (2017) Increased lateral tibial slope predicts high-grade rotatory knee laxity pre-operatively in ACL reconstruction. *Knee Surg Sports Traumatol Arthrosc* 25:1170–1176
23. Sadlo PA, Nebelung W (2006) Arthroscopically Assisted Reduction of a lateral femoral notch in acute tear of the anterior cruciate ligament. *Arthroscopy* 22:574.e571–574.e573
24. Speer KP, Warren RF, Wickiewicz TL, Horowitz L, Henderson L (1995) Observations on the injury mechanism of anterior cruciate ligament tears in skiers. *Am J Sports Med* 23:77–81
25. Tauber M, Fox M, Koller H, Klampfer H, Resch H (2008) Arthroscopic treatment of a large lateral femoral notch in acute anterior cruciate ligament tear. *Arch Orthop Trauma Surg* 128:1313–1316
26. Warren R, Kaplan N, Bach B (1988) The lateral notch sign of anterior cruciate ligament insufficiency. *Am J Knee Surg* 1:119–124
27. Woo SL, Kanamori A, Zeminski J, Yagi M, Papageorgiou C, Fu FH (2002) The effectiveness of reconstruction of the anterior cruciate ligament with hamstrings and patellar tendon. *J Bone Joint Surg Am* 84:907–914