

# Arthroscopy of the Elbow: The Basics

*Jeremy Burnham, Kevin Murr, Srinath Kamineni*

## Introduction

Elbow arthroscopy can be used for multiple diagnostic and therapeutic interventions of the elbow. It involves the use of a 30° or 70° arthroscopic scope and multiple specially designed instruments to provide minimally invasive access to the elbow. Although the utilization of elbow arthroscopy has increased in recent years, it continues to pose a higher risk for injury than arthroscopy of most other joints. The surgeon must possess expert knowledge of elbow anatomy and command a high level of skill in order to safely perform arthroscopic surgery of the elbow.

## Brief History

The first mention of elbow arthroscopy was by Michael Burman in 1931. He began by performing arthroscopic procedures in the elbows of cadavers. However, after attempting this surgery in humans 1 year later, he stated that the elbow was unsuitable for arthroscopy and furthermore that “anterior puncture of the elbow is out of the question”. It was not until 1971 that Watanabe developed a 1.7 mm arthroscope for use in small joints, and several approaches to elbow arthroscopy were subsequently described. K Ito reported a clinical study based on 226 cases in 1981, and Hempfling described the prone position in 1983. Andrews and Carson described their 12 case series in 1985 and reviewed the technique and anatomy of the elbow. More recently, Poehling and Lidenfeld described new approaches in 1989 and 1990, respectively.

## Indications and Contraindications

The indications for elbow arthroscopy are constantly evolving and multiplying. Elbow arthroscopy can be used for debridement of septic arthritis, excision of osteophytes, excision of the radial head, removal of loose bodies, synovectomy, as well as treatment of chondromalacia, arthrofibrosis and joint contracture, and posterior

impingement. It has also been used extra-articularly to perform nerve releases, instability repair, partial or full biceps repairs (often arthroscopically-assisted, and debridement of olecranon bursitis).

Relative contraindications include recent joint or soft tissue infection, the presences of cellulitis, developmental changes, previous trauma or surgery that may alter the normal anatomy, extensive heterotopic ossification, a diagnosis of complex regional pain syndrome, or conditions that prevent distention of the elbow capsule. Previous ulnar nerve transposition may require exposure of the ulnar nerve prior to establishing the anteromedial portal.

## Equipment

We recommend having both 30° and 70° scopes available. We find that 4 mm and smaller scopes are the most effective to use in a medium joint such as the elbow. The surgeon may use a standard arthroscopic pump system, although the senior author prefers the use of gravity saline bags hung 2–3 feet above the operative field. This is an effective option, and far more cost-effective than fluid pumps. These bags can be raised or lowered to change the fluid pressure and rate of flow. Depending on the procedure being performed, one will also need a variety of graspers, biters, arthroscopic scissors, shavers, a radiofrequency probe, and retractors (**Fig. 1**). A sterile or nonsterile tourniquet can be used, and must be placed high on the upper arm.

## Technique: Set Up

Proper positioning of the patient is essential for successful elbow arthroscopy. Poor positioning can lead to difficult access and instrumentation, as well as a poor view of the anatomy, and can lead to an increase risk of injury and increased operative times. There are four main ways in which to position the patient—(1) the supine cross-body, (2) supine (3) suspended, (4) lateral decubitus (author’s preferred position), and prone positions (**Fig. 2**). Occasionally positioning may be dictated by the procedure

being performed, such as concurrent or consecutive open and arthroscopic procedures, although it is chosen according to surgeon preference.

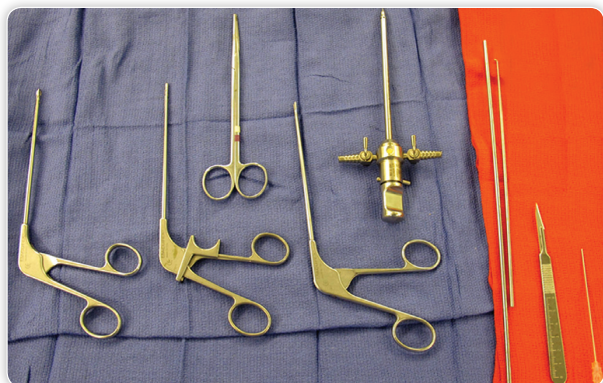The prone and lateral decubitus positions are used most commonly. Poehling first described the prone position in 1989. Many surgeons favor this position because it provides improved access to the patient's elbow (especially the posterior compartment), and it is easier to place the patient in an inherently stable position. However, care must be used when positioning in this manner.

The chest should be padded with gel-filled chest rolls, and the abdomen should be allowed to hang free. The knees should be padded and flexed so that there is minimal traction on the sciatic nerve. The contralateral arm should also be positioned and padded properly to avoid traction and compression injuries to the nerves. The operative arm is then draped over a padded arm board or hand table such that the humerus is parallel to the ground and the forearm is hanging freely in a vertical position. One should

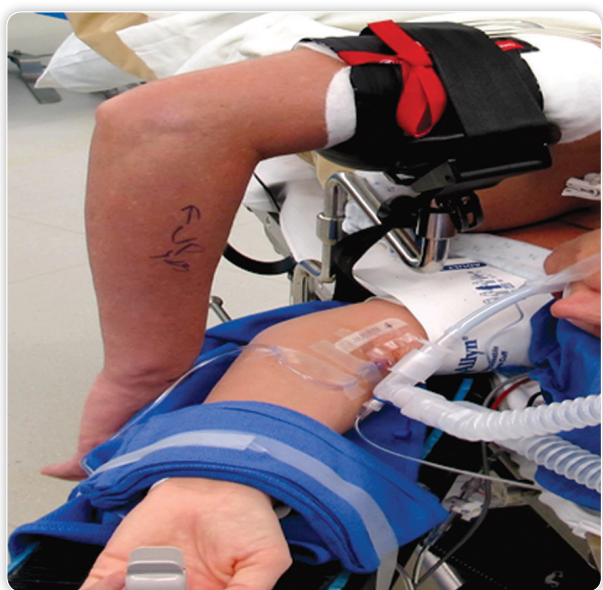
consider choosing a different position for extremely obese patients or patients with respiratory compromise.

O'Driscoll and Morrey described the lateral position in 1992. In the lateral position, the patient is placed in a lateral decubitus position with the assistance of a beanbag or similar device. The upper arm is draped over a padded horizontal post, providing equal access to the anterior and posterior compartments. The lateral position offers many of the benefits of the prone position while overcoming many of the drawbacks, such as providing easier access to the airway.

The supine position was most notably described by Andrews and Carson, and can be utilized with the operative extremity in the cross-body position or with it suspended by an overhead suspension device. The cross-body position is particularly useful when performing a joint arthroscopic and open procedure, as it allows both procedures to be completed without repositioning. The advantage of the supine position is that it provides easier access to the airway for the anesthesia provider, and easy access to the anterior compartment for the surgeon. The drawbacks of the suspended position are that the arm is not stabilized and may swing freely during surgery, and the arthroscope may be more prone to fall out.



**Fig. 1** Basic instruments for an elbow arthroscopy

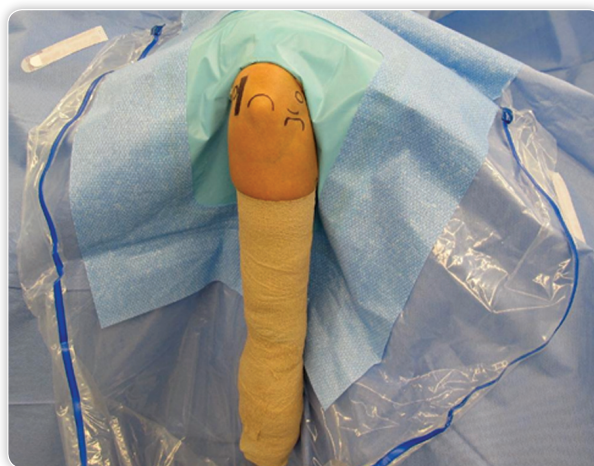

**Fig. 2** Lateral decubitus positioning of the patient with a tourniquet placed on the arm, an arm holder, and the opposite arm supported and padded

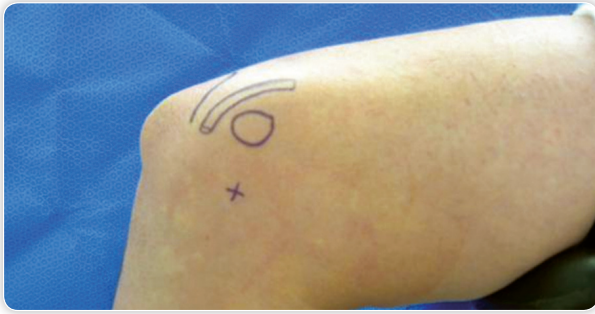### Skin Preparation and Draping

The skin should be cleaned with alcohol if needed, prior to surgical preparation. Either chlorhexidine or betadine solutions can be used to prepare the skin, with the option of iodine plastic wrap if desired. Draping should allow a full arc of access to the joint by the instruments. The author prefers a single extremity drape with a fluid pouch for ease of draping, and cost-efficiency (**Fig. 3**).

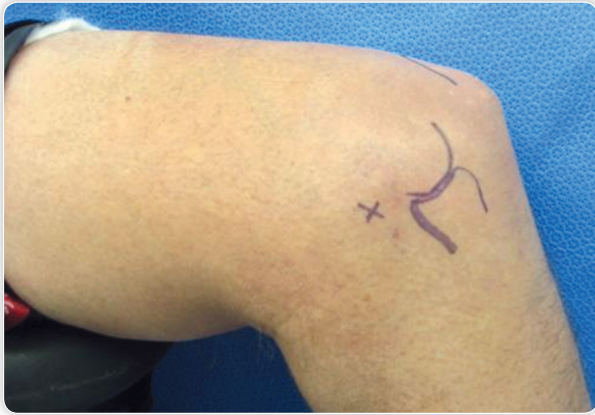
Prior to commencing the procedure, and especially when learning or inexperienced at this technique, the relevant skin marking should be made as shown in **Figures 4 and 5**. At the minimum, these should include the medial epicondyle, the lateral epicondyle, the radiocapitellar joint, the olecranon, and the ulnar nerve. It is important to palpate and inspect the ulnar nerve to ensure that it is not subluxing with elbow flexion and that it has not previously been transposed. The "soft spot", or anconeus



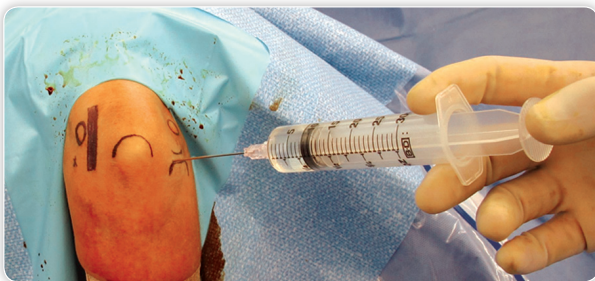**Fig. 3** The arm is marked, prepared with betadine, and draped with a single extremity drape



**Fig. 4** Lateral decubitus positioning with a medial view. The olecranon, medial epicondyle ulna nerve and the anteromedial portal are marked on the skin



**Fig. 5** Lateral decubitus positioning with a lateral view. The olecranon, lateral epicondyle, radial head and the anterolateral portal are marked on the skin



**Fig. 6** Joint insufflation through the posterior soft-spot portal with normal saline

triangle, should also be palpated. This is the center of a triangle that is formed by the lateral epicondyle, the radial head, and the olecranon. A large bore needle should then be used to enter the joint through the “soft spot” and the surgeon should inject 30–50 mL of saline solution to distend the joint (**Fig. 6**). This distension causes anterior displacement of the neurovascular structures and allows for safer access to the joint.

### Technique: Portal Placement

Multiple portals have been described in the literature. These can be grouped into three main groups:

1. The anteromedial portals.
2. The anterolateral portals.
3. The posterior portals.

Most surgeons make one of the anterior portals first, and then create the second anterior portal with either an outside-in or inside-out approach. There is debate as to whether the first portal should be the anteromedial or anterolateral portal. There are good reasons to support both methods. It is generally accepted that it is safer to start with the medial portal, as cadaveric studies have shown the distance between the medial portal and the median nerve to be greater than the distance from the lateral portal to the radial nerve.

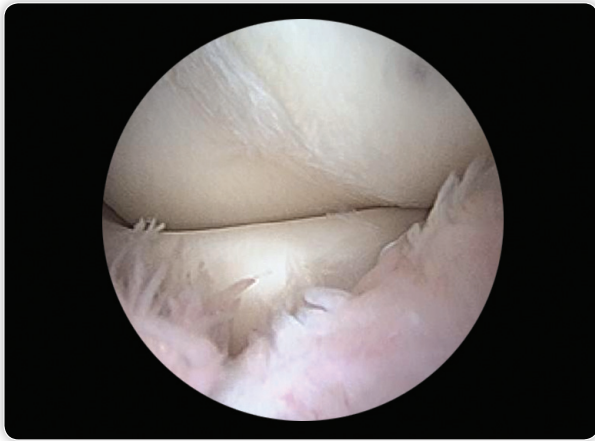
To create the portal, a scalpel is first used to make a skin incision. Care should be used to prevent penetration of the scalpel into the subcutaneous tissues as this could damage superficial sensory nerves. We then use a hemostat or similar blunt-tipped instrument to perform blunt dissection to the joint capsule. A 4.0 mm blunt trocar is then used to penetrate the joint. Successful entry into the joint will be indicated by a gush of saline solution from the portal. The second portal can then be created by placing a spinal needle into the joint under arthroscopic visualization.

### Anteromedial Portals

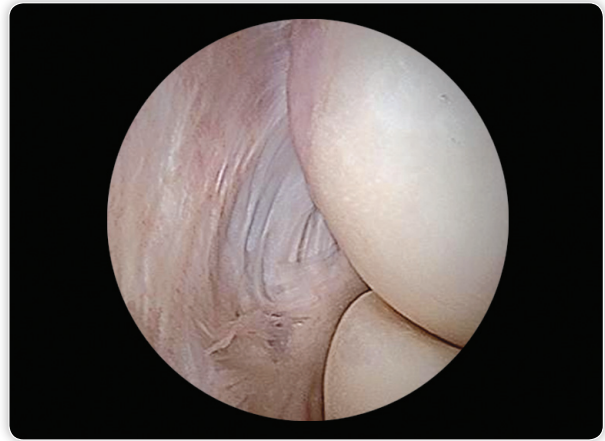Although the medial antebrachial cutaneous nerve is most at risk from anteromedial portals, the median nerve and the brachial artery are also at risk when placing anteromedial portals. The anteromedial portal group consists of three commonly used portals—(1) the standard, (2) mid, and (3) proximal anteromedial portals.

The proximal anteromedial portal is commonly considered the main diagnostic portal, especially when the patient is in the prone or lateral decubitus position. This portal is described by Poehling as being located 2 cm proximal to the medial epicondyle and just anterior to the intermuscular septum. The surgeon should locate the intermuscular septum with his hand and advance the trocar just anterior to it, preventing damage to the ulnar nerve. The trocar is advanced while making contact with the humerus and directed toward the radial head. This portal allows excellent visualization of the radiocapitellar joint. Stothers found that the median nerve was an average of 12.4 mm away from this proximal anteromedial portal when the elbow was in flexion.

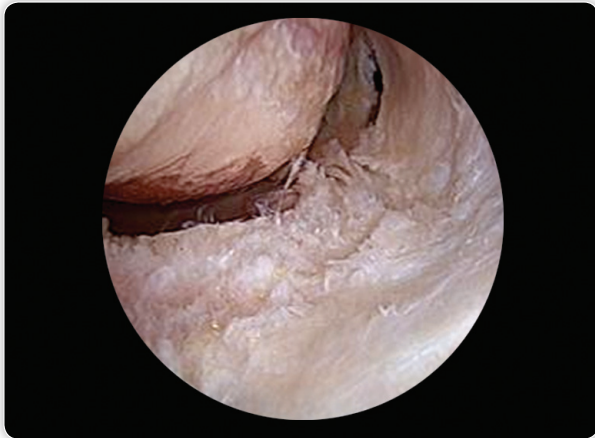
The standard anteromedial portal is another commonly used anteromedial portal. It is located 2 cm anterior and 2 cm distal to the medial epicondyle. This portal pierces the common flexor origin and is located closer to the median nerve and brachial artery than the proximal anteromedial portal (average of 7 mm from the median nerve and 15 mm from the brachial artery in flexion). The cannula must be advanced laterally toward the median nerve. As with the proximal anteromedial portal, the ulnar nerve is usually safe as long as the portal is placed anterior to the anterior intermuscular septum. This portal can be used as an accessory portal or to provide better visualization of the anterolateral elbow joint. The mid-ant anteromedial portal is a modification of the proximal anteromedial portal and is located 1 cm anterior and 1 cm proximal to the medial epicondyle. This is less commonly used, although it does allow the trocar to be advanced distally toward the center of the joint as it is more proximal than the



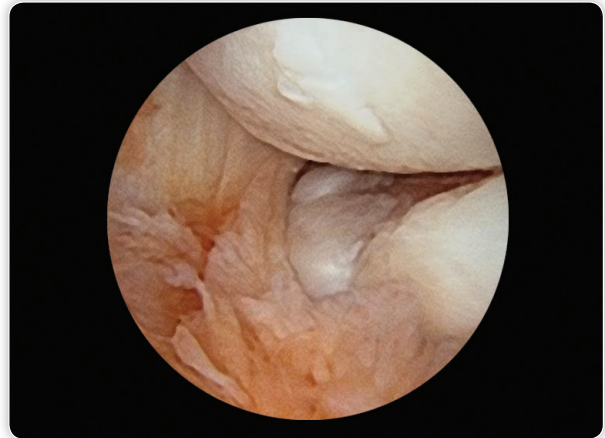
**Fig. 7** Synovitis around the radiocapitellar joint, visible through the anteromedial portal



**Fig. 9** Lateral epicondylitis as viewed through the anteromedial portal



**Fig. 8** Cartilage loss in the radiocapitellar joint as seen through the anteromedial portal



**Fig. 10** A malunited radial head fracture and secondary arthritis as viewed through the anteromedial portal

mid-antromedial portal. Examples of the view from the anteromedial portal are shown in **Figures 7 to 10**.

### Anterolateral Portals

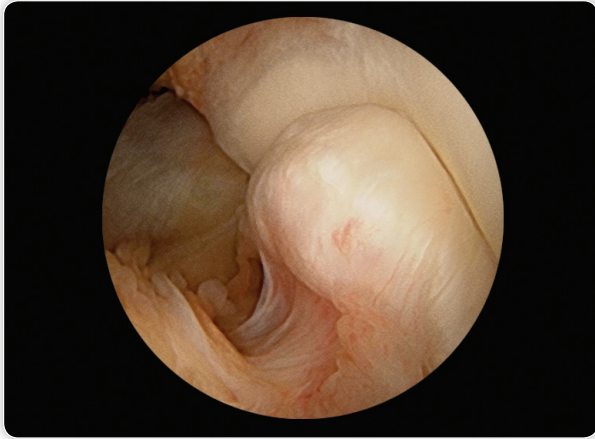
The anterolateral portals consist of the distal anterolateral portal, the mid-antrolateral portal, and the proximal anterolateral portal. The radial nerve and posterior interosseous nerve are at risk during placement of anterolateral portals. This risk can be decreased by creating a medial portal first, and then using the arthroscope light to transilluminate the skin in the area of the anterolateral portal. The nerve often creates a silhouette and can be avoided during placement using this technique. Andrews and Carson first described the anterolateral portal 3 cm distal and 1 cm anterior to the lateral epicondyle. Their description is now considered to be consistent with the distal anterolateral portal. This portal is now used less commonly than the others due to its proximity to the nerve, shown in some cases to be less than 0.5 cm from the nerve.

The mid-antrolateral portal is located proximally to the distal anterolateral portal and is generally considered to be safer than the

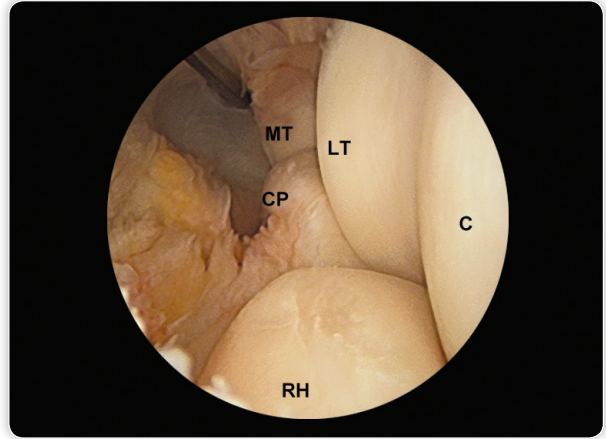
distal portal. It is described as being 1 cm anterior to the lateral epicondyle and anterior to the radiocapitellar joint space. The portal is located approximately 10–11 mm away from the nerve in this location. Stothers described a proximal anterolateral portal located 1–2 cm proximal to the lateral epicondyle and centered directly on the anterior surface of the humerus. The sheath and trocar are directed toward the center of the joint and kept in contact with the anterior surface of the humerus, similar to the proximal anteromedial portal. The trocar pierces the brachioradialis and the brachialis before entering the joint capsule. Stothers found that the radial nerve was approximately 10 mm away from the portal site when the elbow was held in flexion. Several studies have also shown improved visualization of the elbow when using the more proximal anterolateral portal. Examples of the view from the anterolateral portal are shown in **Figures 11 to 13**.

### Posterior Portals

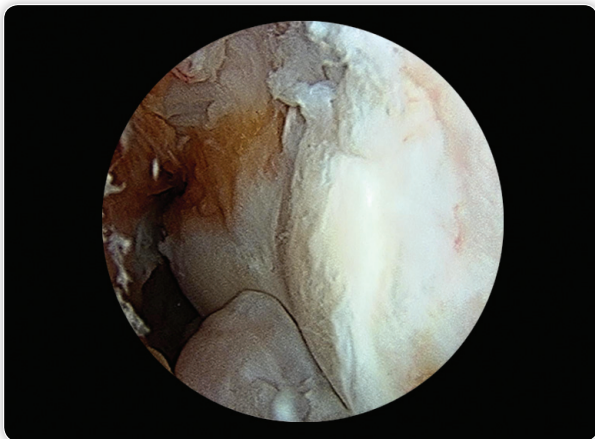
The posterior portals are considered relatively safe compared to the anterior portals. The posterior portals consist of several variations including the straight posterior portal, the posterolateral portal,



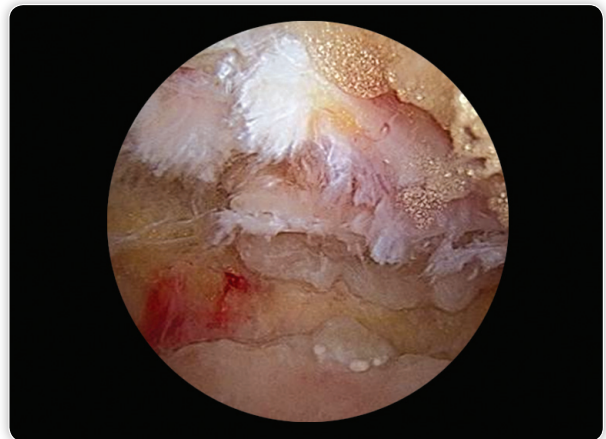**Fig. 11** Lateral viewing portal with a view of a normal coronoid process and pristine trochlea



**Fig. 13** Lateral viewing portal demonstrating medial trochlea (MT), lateral trochlea (LT), capitellum (C), coronoid process (CP), and radial head (RH)



**Fig. 12** Lateral viewing portal demonstrating the coronoid (with early osteophytes) and the trochlea with articular cartilage degenerative changes



**Fig. 14** Kissing osteophytes as seen through the direct posterior portal, posterior impingement

the direct posterolateral portal, and the lateral radiocapitellar portal. The direct posterior and the posterolateral portal are the most commonly used.

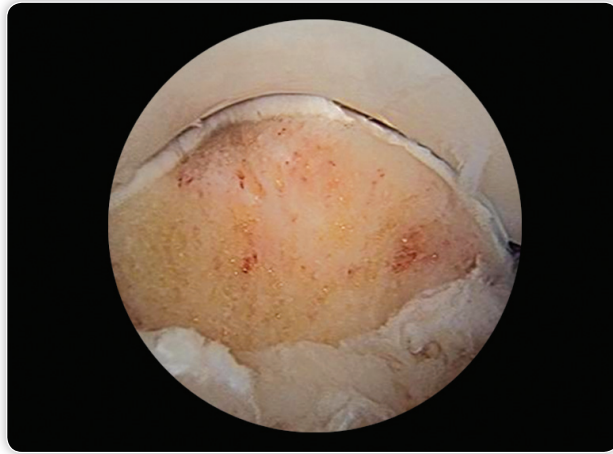
The posterolateral portal is usually the first posterior portal to be established. It is located 3 cm proximal to the olecranon, along the lateral border of the triceps tendon. The trocar and sheath are advanced distal and medially, with the elbow in approximately 20–30° of flexion to relax the posterior structures. A 2.7 mm scope can be used to allow easier access into the posterior aspect of the joint. It is often difficult to visualize the lateral portion of the posterior joint, and a direct posterior portal is often used in tandem with this portal.

The direct posterior portal is located 1.5–2 cm proximal to the tip of the olecranon, directly over the triceps tendon. After the skin incision is made, a blunt trocar and sheath are advanced directly into the olecranon fossa. This can be done under arthroscopic visualization using the posterolateral portal. This portal is primarily used for placement of instrumentation, however, the arthroscope can be placed in this portal, allowing the posterolateral portal to be used for

instrumentation. The direct posterior portal allows visualization of the entire posterior aspect of the elbow joint. Examples of the view from the posterior portal are shown in **Figures 14 to 16**.

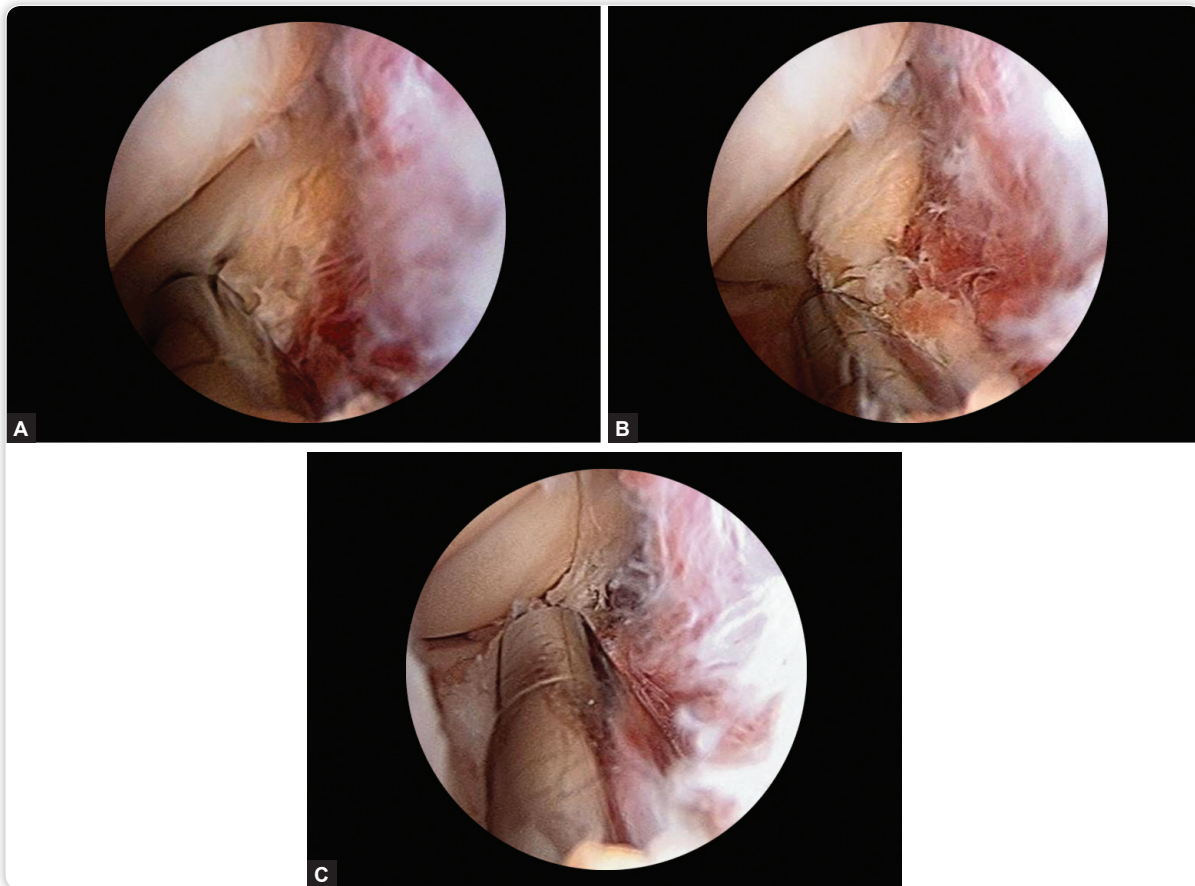
### Pearls and Tips

- Draping and positioning must allow circumferential access to the elbow and provide adequate room for the surgeon's hands and the arthroscope.
- Palpable landmarks and the portal sites must be marked prior to insufflation of the joint.
- Portal sites should be established with a skin incision and then blunt dissection to the capsule to avoid neurovascular injury.
- A thorough history and physical should be completed prior to the surgery to examine any possible previous surgeries near the elbow or anatomic abnormalities that may distort the normal anatomy of the neurovascular structures.
- The elbow should be flexed to 90° when establishing anterior portals.



**Fig. 15** Posterior portal demonstrating a partial olecranon resection following treatment for posterior impingement

- Suction tubing should be set to gravity only to prevent important structures from being sucked into the shaver.
- The arthroscope light can be used to transilluminate the skin for subsequent portal sites to allow visual identification of crossing neurovascular structures.
- It is controversial whether to establish the anteromedial or the anterolateral portal first. This should be decided according to surgeon experience and comfort.
- Sharp trocars are generally avoided, although one should take special care to ensure that the blunt trocar does not slide side-to-side when attempting to pierce the joint capsule.
- The olecranon fossa is often filled with fat and fibrous tissue that needs to be debrided to allow an adequate view of the posterior elbow.
- A complete range of motion examination should be performed and documented at the conclusion of the procedure, including flexion, extension, supination, and pronation.
- The surgeon's skill and experience level should dictate the complexity of the surgical procedure attempted.



**Figs 16A to C** Posterior lateral gutter viewed through the posterior midline portal (working posterolateral portal) demonstrating excision of a posterolateral plica

## Bibliography

1. Adams J, Steinmann S. Arthroscopy of the elbow: setup and portals. In: Lee D, Neviasser R (Eds). *Operative techniques: shoulder and elbow surgery*. Philadelphia, PA: Elsevier Saunders; 2011. pp. 664-7
2. Andrews JR, Carson WG. Arthroscopy of the elbow. *Arthroscopy*. 1985;1(2):97-107.
3. Baker CL, Jones GL. Arthroscopy of the elbow. *Am J Sports Med*. 1999;27(2):251-64.
4. Conway JE. *Elbow arthroscopy: the basics operative techniques in orthopaedic surgery*, 1st edition. Philadelphia: Lippincott Williams & Wilkins; 2010. pp. 145-54.
5. Dugas J, Bullens-Borrow A. Instability and arthroscopy. In: Johnson DL, Mair S (Eds). *Clinical Sports Medicine*. Philadelphia, PA: Mosby, Inc.; 2006. pp. 348-50.
6. Funk L, Nicoletti S. Treatment by arthroscopy. In: Stanley D, Trail I (Eds). *Operative elbow surgery*. Oxford: Elsevier Health Sciences; 2011. pp. 437-52.
7. Miller M, Hart J. Elbow Arthroscopy. In: DeLee J, Drez D, Miller M (Eds). *DeLee and Drez's Orthopaedic Sports Medicine*, 3rd edition. Philadelphia, PA: Saunders, 2010.
8. O'Driscoll SW, Morrey BF. Arthroscopy of the elbow. Diagnostic and therapeutic benefits and hazards. *J Bone Joint Surg Am*. 1992;74(1):84-94.
9. Poehling GG, Ekman EF. Arthroscopy of the elbow. *Instr Course Lect*. 1995;44:217-23.
10. Poehling GG, Whipple TL, Sisco L, et al. Elbow arthroscopy: a new technique. *Arthroscopy*. 1989;5(3):222-4.
11. Stothers K, Day B, Regan WR. Arthroscopy of the elbow: anatomy, portal sites, and a description of the proximal lateral portal. *Arthroscopy*. 1995;11(4):449-57.